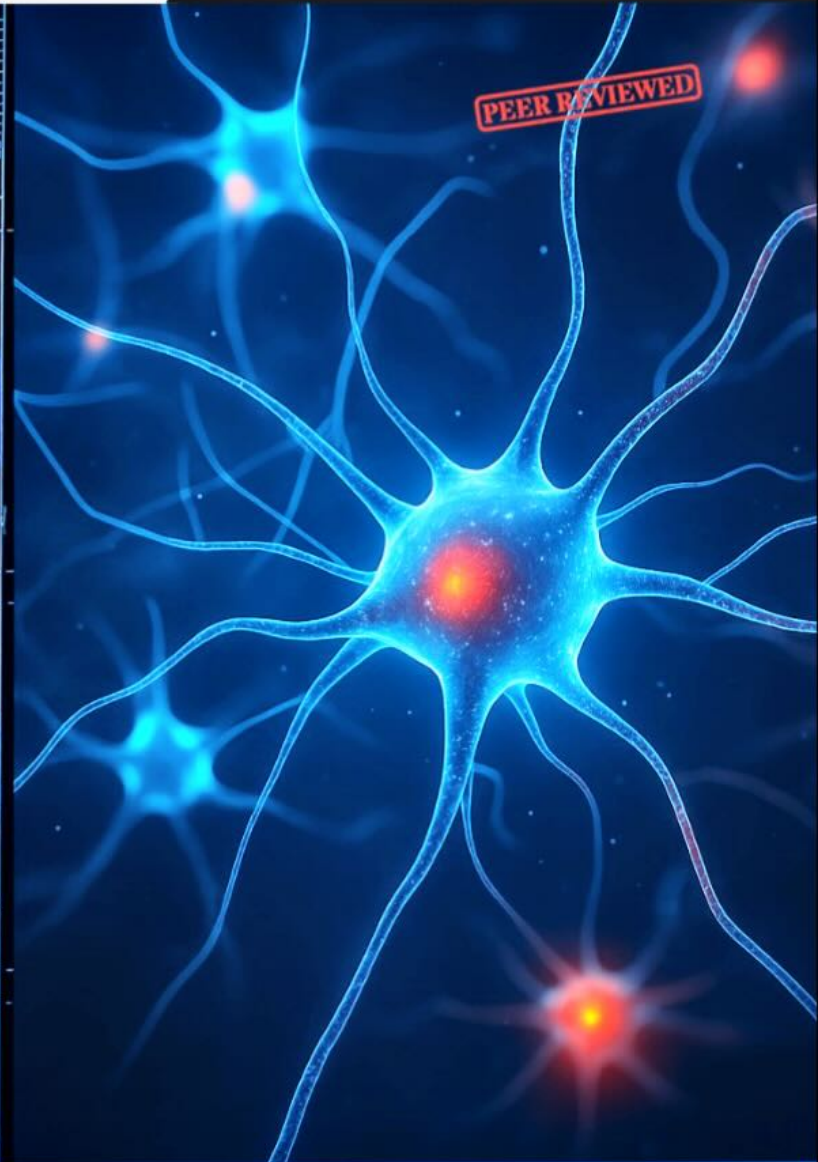
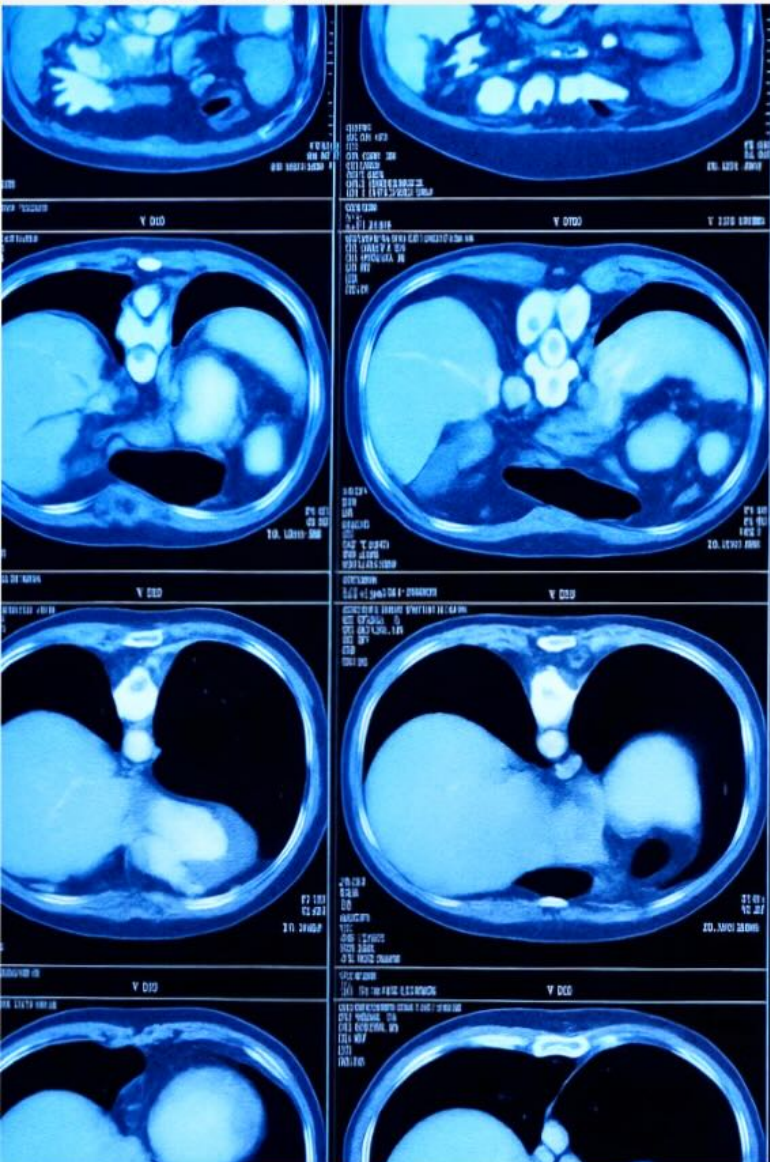


THE HOMOEOPATHIC HERITAGE

Bringing Classical and Contemporary Homoeopathy Together

ISSN: 9070-6038

Vol. 51, No. 9, December 2025



Homeopathy in Neurological Problems

- Hereditary Neuropathy: Genetic Foundation & Homoeopathy- Dynamic Approach
- Integrative Management of Type 2 Diabetes Mellitus: An Observational Study on the Use of Homoeopathic Mother Tinctures Alongside Allopathic Antidiabetics

THE HOMOEOPATHIC HERITAGE

Vol. 51, No.9, December 2025

Pages: 136

CHIEF EDITOR

Dr Farokh J. Master

EDITORIAL TEAM

Dr Mansi Tyagi

LANGUAGE EDITOR

Dayna Lynn Davis

CHIEF ASSOCIATE EDITOR

Dr Yogesh Niturkar

ASSOCIATE EDITORS

Dr Ruby Dubey

Dr Amit Sahani

Dr Anit Acharya

Dr Anum Zaheer

Dr Geeta Rani Arora

Dr Hitarth Mehta

Dr Kavitha Kukunoor

Dr Krutik Shah

Dr Manpreet Kaur

Dr Niharika Jain

Dr Poorav Desai

Dr Preeti Jha

Dr Shilpi Rastogi

Dr Shweta Singh

REVIEWERS

Dr Ashish Indani

Dr Clare Relton

Dr Chaturbhuj Nayak

Dr Eswara Das

Francis Treuherz

Dr Kamal Sethi

Dr Monika Kathuria

Dr Queenita Fernandes

Dr Raj Kumar Manchanda

Dr Robert Mathie

Dr Sandeep Sathye

Dr Yashveer

INTERNATIONAL ADVISORS

Dr Ajit Kulkarni

Dr Bipin Jain

Chaim Rosenthal

Frederik Schroyens

Grant Bentley

Jan Scholten

Jeremy Sherr

Dr Kamlesh Mehta

Luc De Schepper

Dr L.M. Khan

Miranda Castro

Dr M.K. Sahani

Dr P. K. Sudhir

Dr Rajat Chattopadhyay

Richard Moskowitz

Roberto Petrucci

Dr Sanjay Sehgal

Dr Subhas Singh

Dr Subrata Kumar Banerjea

Dr Tarkeshwar Jain

Todd Rowe

Torako Yui

Dr Uttareshwar R. Pachegaonkar

Dr Yogesh Sehgal

EDITORIAL LEGACY: MENTORS

Dr D. P. Rastogi

Dr H. L. Chitkara

Dr Praful Vijayakar

Dr Robin Murphy

Dr S. P. Koppikar

BUSINESS CONSULTANT

Manish Jain

Published by: Mr Kuldeep Jain on behalf of
M/s. B. Jain Publishers (P) Ltd.

Printed at M/s Narain Printers & Binders,
D-6, Sector-63, NOIDA, UP-201307

Published from 1921/10, Chuna Mandi,
New Delhi - 110055

Ph.: 91-11-4567 1000

Email: hheditor@bjain.com

Corporate Office: 0120-4933333

Disclaimer: The Publishers are not liable for manuscripts not sent on the Publisher's demand. In principle, only those papers will be accepted which have not been published previously, domestically or abroad. Furthermore, manuscripts may not be offered to other publications at the same time as they are under consideration for this journal. The article selected can be used in other language editions of the journal. Unsolicited manuscripts will not be returned.

Note: The views and opinions expressed by the authors of articles published in this journal are not necessarily those of the editors and publishers.

Effectiveness of Homeopathy in treatment of Psoriasis: A Case Report

Dr. Polaju Sravan Kumar

PG Scholar, Dept of Materia Medica

JSPS Government Homoeopathic Medical College, Ramanthapur, Hyderabad



Abstract

Psoriasis is a non-contagious, chronic Auto immune skin condition that produces plaques of thickened, scaling skin. The dry flakes of skin scales result from the excessively rapid proliferation of skin cells. Psoriasis is generally thought to be a genetic disease which is triggered by environmental factors. It can occur at any age, although it most commonly appears for the first time between the ages of 15 and 25 years. Approximately one third of people with psoriasis reports being diagnosed before age 20. In India the prevalence of psoriasis varies from 0.44 to 2.8%, it is twice more common in males compared to females, and most of the patients are in their third or fourth decade at the time of presentation. In addition to the appearance and distribution of the rash, specific medical signs may be used by medical practitioners to assist with diagnosis. These may include Auspitz's sign (pinpoint bleeding when scale is removed), Koebner phenomenon (psoriatic skin lesions induced by trauma to the skin).

Case summary: We present here a case report of a 38-year-old male with psoriatic lesions on the hands for 10 years with intolerable itching. The present case was completely cured after 1 year of regular treatment with individualised homoeopathic medicine without any adverse effects. After detailed case taking, Merc sol 200C was administered. The Modified Naranjo criteria for Homoeopathy (MONARCH) was used for assessing causal attribution, where the score was +8, suggesting that the clinical improvement was the result of the homoeopathic treatment. Before and after treatment photographs were taken to assess the improvement. This evidence-based case could pave way for further research into using

individualised homoeopathy for psoriasis.

Keywords

Merc. Sol, Auspitz's sign, Koebner phenomenon, Homoeopathy, Psoriasis

Introduction

Psoriasis is a non-contagious autoimmune disease of the skin and joints. The word psoriasis is derived from the Greek word 'Psora' meaning itching and 'Iasis' means pain.¹ Psoriasis affects the skin and nails and is known to have many complications. The disease can either be localised or generalised and the lesions are usually symmetrical, well-defined red pustular plaques, often covered with white or silvery scales. It mainly causes itching and pain.² Psoriasis can affect physically, emotionally and socially. Overall quality of life is often greatly affected too. The most common symptoms of psoriasis reported by patients are skin peeling: 92%, pruritus: 72%, erythema: 69%, fatigue: 27%, swelling: 23%, burning: 20%, bleeding: 20% and pain.³ Chronic plaque-type psoriasis accounts for about 90% of all cases of the disease. Sharply defined, erythematous, pruritic plaques covered in silvery scales are the hallmark clinical symptoms. Large amount of skin can be covered by the plaques if they merge. The scalp, the extensor surfaces of the limbs and the trunk are typical sites.^{4,5} Multiple studies have explored the efficacy of homoeopathic treatment in cases of psoriasis. In a prospective, multicentric observational study evaluating the details and impact of homoeopathic treatment in psoriasis patients receiving standard medical care, diagnoses and severity of symptoms notably improved, yielding large

effect sizes. In addition, there was a marked improvement in the patients' quality of life, coupled with a significant reduction in conventional treatment usage and health-care service utilisation.⁶ A case series describes the potential usefulness of classical homoeopathy in addressing psoriasis and associated outcomes. It presents six psoriasis cases with varying degrees of severity. Erythroderma was reported to occur in two cases, one of which progressed to septicemia. All of them received individualised homoeopathic treatment, and as a result, the overall health and Psoriasis Area and Severity Index (PASI) scores of the patients improved.⁷ In another case report, regular homoeopathic treatment significantly reduced the severity of psoriasis and improved quality of life.⁸ Various other studies also provide evidence in favour of homoeopathic treatment for different types of psoriasis, without any side effects.⁹⁻¹² This case report is an attempt to emphasise the positive effect of individualised treatment of psoriasis with Homoeopathy.

Methodology:

Patient Information:

On February 4, 2024, a 38-year-old male patient, a schoolteacher, presented with raised, scaly lesions persisting for 10 years, predominantly affecting his hands which tends him to scratch. The lesions were red with marked scaling and intolerable itching. Patient was apparently healthy 10 years back, the complaint started initially as itching over both upper limbs. He neglected it as some allergy, and it slowly started to spread all over the upper limbs. Simultaneously the intensity of itching is also increased, so he consulted Allopathic doctors, and they diagnosed him with Psoriasis, he used many allopathic medicines and ointments almost for 5 years but there is only temporary relief. He came to the OPD with severe itching all over the body and explaining that 'this is my last hope to get rid of this complaint'. Initially when the complaint started there was no falling of white flakes, but at present there are scaly eruptions with falling of white flakes on scratching. The patient complains of severe itching with a desire to scratch the part until it becomes red. Along with itching there is burning sensation near the eruptions. The eruptions look scaly and irregular in

patches, the skin becomes moist after scratching. He covers his hands with full shirt in front of others which causes sweating, which in turn causes itching. Itching also gets aggravated at night, lying on bed, cold weather and on mental exertion, amelioration on sleeping.

Patient had a history of attack of typhoid fever 4 years back, used allopathic medication and got cured.

Patient had a history of Internal hemorrhoids 12 years back, used ayurvedic medicines and got relieved.

No relevant history running in the family.

Patient hails from middle socioeconomic family, he is the younger child in his family. During his schooling he was very much interested in studies and he always wants to be first in his academics. At present he is Private school principal in Saroornagar, Hyderabad. He maintains good and healthy relationship with friends and family members. Since last 2 years he was mentally suffering about his wife, who works as lab nurse in the hospital. His wife got addicted to drugs which are used as anesthetics in her hospital. Initially she used to take pills but now she started taking injections and got addicted to it. The hospital management came to know about this and took a severe action and detained her from the work. All the friends and family members came to know about this, and some issues happened in the family. All those things made this person to suffer mentally, even though he is mentally suffering he supported his wife in a positive way. Whenever he thinks about this issue and his wife, he feels very much depressed and sad. When anyone asks about his wife, he feels that "what i have done as a husband is not at all good and responsible, iam waste of living". He feels dissatisfied about himself as a husband. All those mental sufferings make his complaints worse.

Generals:

The patient had a good appetite, and he uses to drink cold water to get his thirst satisfied. She had a desire for cold milk. No peculiar desires, aversions, he has regular bowels with soft stools and urine is clear without any burning. He has

Case Report

excessive perspiration while eating, no peculiar odor of sweat.

Clinical Findings:

The site of onset of the lesions was on his both hands. The erythematous plaques of varying size, covered with white scales, on thick and dry well-demarcated body were found to be present on the affected sites. The distribution of scales was symmetrical, bilateral and scattered all over the body.

Mansion the Miasm

Totality Of Symptoms:

After analysis and evaluation of the symptoms, the totality was constructed based on the following symptoms:

1. He doesn't want to live, loathing of life
2. Depressed and sad.
3. Dissatisfied about himself
4. Desires cold water.
5. Itching of Skin eruptions at night
6. Itching of Skin eruptions aggravated at warmth of bed
7. Burning sensation of skin after scratching.
8. Itching of skin after mental exertion
9. Itching of skin better after sleeping.
10. Perspiration while eating.

Software Used: Repertorisation was done with the help of Hompath software.

Figure-1 Repertorisation chart



Therapeutic Intervention:

After repertorisation, Merc sol, Sepia, Rhustox and Arsenic alb came up as the leading medicines

[Figure 1]. Merc sol was finally selected, conforming to Materia medica, and covered all the symptoms.¹³

The potency and dosage were determined based on the susceptibility as per the patient's age, pathology and the disease's nature. All the medicines were administered orally. Three doses consisted of six medicated globules of size 30 for the first 3 days followed by identical looking placebo. Placebos were advised to be taken twice daily every day for 30 days.¹⁴

Follow Up & Outcome:

After the administration of this remedy twice over the course of 1-year, Psoriatic patches from hands completely disappeared with the individualised homoeopathic treatment. Photographic evidence collected before, and after the treatment are presented in Figures 2-6. The follow-up details are given in Table 1.

Table.1 Follow-up details.

FOLLOW UP DATE	INDICATION OF PRESCRIPTION	MEDICINE WITH DOSE
4/02/2024	Psoriatic lesions with intense itching and burning. Aggravated at night and warmth of bed. Ameliorated after sleep.	Merc sol 200-3doses
10/03/2024	Pt is feeling better regarding itching and eruptions. Redness and falling of flakes reduced slightly. Generals are good. He explains about relief of 25% in his complaints	Rubrum (4-4) 1month
09/04/2024	Pt is feeling better regarding itching and eruptions. Redness and falling of flakes reduced slightly. Generals are good. He explains about relief of 30% in his complaints	Rubrum (4-4) 1month
01/05/2024	Pt explains the condition is same as in the previous visit. No improvement.	Merc sol 1M 1dose

10/06/2024 15/07/2024	<p>Pt is feeling better regarding eruptions and itching as compared to the previous visit.</p> <p>Redness and falling of flakes reduced completely.</p> <p>Generals are good.</p> <p>He explains about relief of 50% in his complaints</p> <p>Pt is feeling better regarding itching and eruptions.</p> <p>Generals are good.</p> <p>He explains about relief of 60% in his complaints</p>	<p>Rubrum (4-4) 1month</p> <p>Rubrum (4-4) 1month</p>
08/08/2024	<p>Pt is feeling better regarding itching and eruptions.</p> <p>Generals are good.</p> <p>Mentally he feels better.</p> <p>He explains about relief of 70% in his complaints</p>	<p>Rubrum (4-4) 1month</p>
19/09/2024	<p>Pt is feeling better regarding itching and eruptions.</p> <p>Generals are good.</p> <p>Mentally he feels better.</p> <p>He explains about relief of 80% in his complaints</p>	<p>Rubrum (4-4) 1month</p>
02/11/2024	<p>Pt is feeling better regarding itching and eruptions.</p> <p>Generals are good.</p> <p>Mentally he feels better.</p> <p>He explains about relief of 90% in his complaints</p>	<p>Rubrum (4-4) 1month</p>
09/01/2025	<p>Pt is feeling better.</p> <p>No scaling, no itching.</p> <p>Mentally he is good.</p> <p>Generals are better.</p>	<p>Rubrum (4-4) 1month</p>

Figure. 1 (04/02/2024)

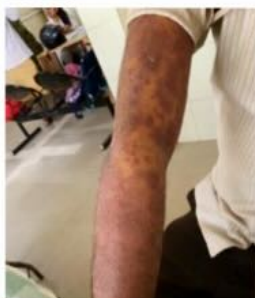

Figure. 2 (10/03/2024)

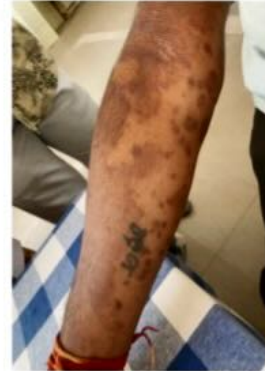

Figure. 3 (10/06/2024)

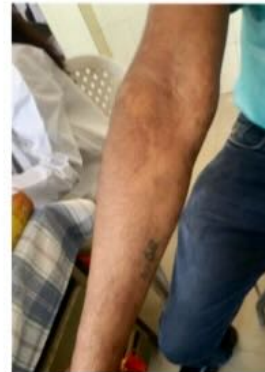

Figure. 4 (19/09/2024)

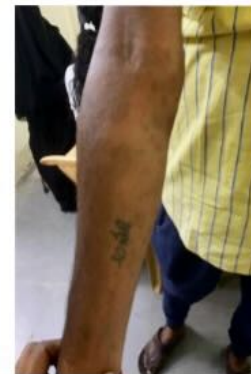
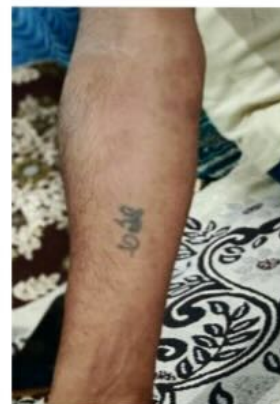
Figure. 5 (09/01/2025)



DISCUSSION

Psoriasis is an autoimmune skin condition, which has a limited scope of treatment in modern medicine. This case report describes the role of the homeopathic medicine Merc sol 200C followed by 1M in treatment of Psoriasis. Merc sol was given after repertorisation and after consultation of *Materia medica*. While upon repertorisation, *Sepia* and *Rhustox* [Figure 1] came close. In this case of Psoriasis, severe symptoms such as scaling, Burning and intolerable itching were seen to improve successfully with Merc sol in 200C and 1M potency. During the follow-ups, all the complaints of the patient progressively decreased without any aggravation, which confirms to Kent’s fourth observation of “no aggravation with recovery of the patient”, which indicates that the patient was given the correct remedy and in the right potency. Dr Hahnemann also mentioned in § 191 ‘Internal administration of a remedy causes important changes in general health and particularly in the affected external parts. It restores health of the entire body, along with the disappearance of the external affections’.¹⁵

The Modified Naranjo Criteria for Homeopathy¹⁶ used for causality assessment showed that homeopathic medication could be the reason behind the improvement in the case, with the score of +8 (Table 2). The patient was further observed for six months. He did not develop any lesions or itching during this period. This case demonstrates that homeopathy, when used with an individualized approach, can be effective in treating plaque psoriasis. As this is a single case study and Psoriasis is notorious to have unpredictable remissions, well-designed, randomised, controlled studies can be used as gold standard for firmer evidence.

Table.2 Modified Naranjo Criteria for Homeopathy (MONARCH)

DOMAINS	YES	NO	N/A
Was there an improvement in the main symptom or condition for which the homeopathic medicine was prescribed?	+2		
Did the clinical improvement occur within a plausible time frame relative to the medicine intake?	+1		

Was there a homeopathic aggravation of symptoms?	0		
Did the effect encompass more than the main symptom or condition (i.e., were other symptoms, not related to the main presenting complaint, improved or changed)?	+1		
Did overall well-being improve? (suggest using a validated scale or mention about changes in physical, emotional and behavioral elements)	+1		
(A) Direction of cure: Did some symptoms improve in the opposite order of the development of symptoms of the disease? (B) Direction of cure: Did at least one of the following aspects apply to the order of improvement in symptoms. -from organs of more importance to those of less importance? -from deeper to more superficial aspects of the individual? -from the top downwards?	0		
Did ‘old symptoms’ (defined as non-seasonal and non-cyclical symptoms that were previously thought to have resolved) reappear temporarily during the course of improvement?		0	
Are there alternative causes (i.e., other than the medicine) that with a high probability – could have produced the improvement? (consider the known course of the disease, other forms of treatment and other clinically relevant interventions)		+1	
Was the health improvement confirmed by any objective evidence? (e.g., investigations, clinical examination, etc.)	+2		
Did repeat dosing, if conducted, create similar clinical improvement?		0	

TOTAL SCORE: +8

Financial Support and Sponsorship None.

Conflicts of Interest The authors declare no conflicts of interest.

Ethics Approval Ethics approval was obtained from the institutional ethics committee prior to the publication of this case report.

Declaration of Patient Consent Written informed consent was obtained from the patient for publication of clinical findings and accompanying images. The patient understands that personal identity will remain confidential and no identifiable information will be disclosed.

CONCLUSION

This case report demonstrates that individualized homeopathic treatment may play a beneficial role in the management of chronic plaque psoriasis. The patient showed progressive improvement in itching, scaling, and plaque formation, suggesting a positive therapeutic response to *Mercurius solubilis* in 200C and 1M potency. The Modified Naranjo Criteria (score +8) further supports the likelihood that the clinical improvement resulted from the prescribed homeopathic intervention rather than spontaneous remission. Although this is a single case study and psoriasis has a fluctuating natural course with periods of remission and exacerbation, the successful outcome observed in this case highlights the potential of homeopathy as a complementary therapeutic approach.

REFERENCES

- Ritchlin CT, Fitzgerald O. Psoriatic and Reactive Arthritis: A Companion to Rheumatology. Philadelphia, PA: Mosby; 2007. p. 256.
- Pariser D, Schenkel B, Carter C, Farahi K, Brown TM, Ellis CN, et al. A multicenter, non-interventional study to evaluate patient-reported experiences of living with psoriasis. *J Dermatol Treat* 2016; 27:19-26.
- World Health Organization. Psoriasis. Available from: <https://www.who.int/docs/default-source/ncds/psoriasis-info-sheet-3.pdf?sfvrsn=a5d14e81> [Last accessed on 2023 Aug 01].
- Ortonne JP, Chimenti S, Luger T, Puig L, Reid F, Trueb RM. Scalp psoriasis: European consensus on grading and treatment algorithm. *J Eur Acad Dermatol Venereol* 2009; 23:1435-44.
- Nestle FO, Kaplan DH, Barker J. Psoriasis. *N Engl J Med* 2009; 361:496-509.
- Witt CM, Ludtke R, Willich SN. Homeopathic treatment of patients with Psoriasis-A prospective observational study with 2 years follow-up. *J Eur Acad Dermatol Venereol* 2009;23:538-43.
- Mahesh S, Shah V, Mallappa M, Vithoulkas G. Psoriasis cases of same diagnosis but different phenotypes-Management through individualized homeopathic therapy. *Clin Case Rep* 2019;7:1499-507.
- Taneja D, Sadhukhan M, Rath P, Sarangi MR, Mittal R, Prusty AK, et al. Open-label study to evaluate the response to homeopathic treatment of psoriasis. *OBM Integr Complement Med* 2022;7:1-19.
- Nwabudike LC. Psoriasis and homeopathy. *Proc Rom Acad Ser* 2011;3:237-42.
- Mandal S, Biswas B. An evidence-based case of planter psoriasis treated by individualized homeopathic medicine. *Int J Ayush Case Rep* 2021; 5:84-90.
- Rahman S, Dey JK. A case report of plantar Psoriasis treated with homeopathy. *Homeopathic Links* 2018; 31:248-53.
- Nagar N, Poswal RK. Efficacy of individualized homeopathic treatment in psoriasis-A case report. *Homeopathic Heritage* 2023; 49:52-4.
- Boericke W. Boerike's New Manual of Homeopathic Treatment with Repertory. 3rd ed. New Delhi: B. Jain Publishers Pvt. Ltd; 2010.
- Close S. Homeopathic posology. In: *The Genius of Homeopathy, Lecture, and Essays on Homeopathic Philosophy*. New Delhi: B. Jain Publishers Pvt. Ltd; 2001. p. 183-212.
- Hahnemann S. *Organon of Medicine*. 6th ed. New Delhi: B. Jain Publishers Pvt. Ltd; 1996. p. 160.
- Lamba CD, Gupta VK, Van Haselen RA, Rutten L, Mahajan N, MollaAM, et al. Evaluation of the modified naranjo criteria for assessing causal attribution of clinical outcome to homeopathic intervention as presented in case reports. *Homeopathy* 2020;109:191-7.



INTERNATIONAL ACADEMY OF
CLASSICAL HOMEOPATHY

UNSURPASSED OPPORTUNITY FOR A PRODUCTIVE LEARNING EXPERIENCE

*E-Learning Course in Classical Homeopathy
by Prof. George Vithoulkas*



+30 (24240) 65142

@academy@vithoulkas.com